



# Evaluation of Weakness

**Matthew Burford, MD**

*Director, Neuromuscular Medicine Fellowship  
Clinical Assistant Professor of Neurology  
The Ohio State University Wexner Medical Center*

**MedNet21**  
Center for Continuing Medical Education

 **THE OHIO STATE UNIVERSITY**  
WEXNER MEDICAL CENTER

## Outline:

Part I – Intro and Central Nervous System  
Causes of Weakness – Dr. Burford

Part II – Peripheral Nervous System  
Causes of Weakness – Dr. Isfort

# **Part I – Intro to Weakness and Central Nervous System**

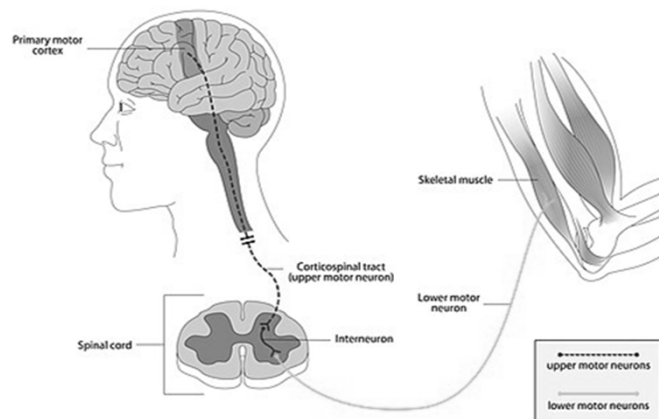
## **Objectives**

- Distinguish between true weakness and mimics
- Identify history questions and clues to identify weakness and begin to localize/formulate differential diagnosis
- Compare upper and lower motor neuron causes of weakness
- Recognize patterns of upper motor neuron weakness
- Appraise cases of upper motor neuron weakness

# Weakness – Defining the Problem

## Weakness – What is it?

- To the neurologist
  - An inability to perform a certain task caused by an inability of the muscle to produce a normal amount of force
  - Caused by a lesion in the motor pathway



[https://commons.wikimedia.org/wiki/File:Illustration\\_of\\_the\\_motor\\_neuron\\_tract\\_descending\\_from\\_primary\\_motor\\_cortex\\_via\\_spinal\\_cord\\_to\\_skeletal\\_muscle.jpg](https://commons.wikimedia.org/wiki/File:Illustration_of_the_motor_neuron_tract_descending_from_primary_motor_cortex_via_spinal_cord_to_skeletal_muscle.jpg)

## Weakness – What is it?

- To the neurologist
  - An inability to perform a certain task caused by an inability of the muscle to produce a normal amount of force
  - Caused by a lesion in the motor pathway
- To the patient
  - An inability to perform in a desired way
  - This ‘weakness’ complaint can include true weakness but may also refer to many other conditions that affect function

## Weakness – The Complaint

- True weakness
  - An inability to perform a certain task caused by an inability of the muscle to produce a normal amount of force
- Fatigue
  - A decline in endurance, focus, or ability with repetitive activity
  - Fatigable weakness – development of true weakness in a muscle group often with task-specific repetition
- Asthenia
  - Generalized weariness or exhaustion in the absence of true weakness

## Weakness – The Complaint

- True weakness
  - An inability to perform a certain task caused by an inability of the muscle to produce a normal amount of force
- Fatigue
  - A decline in endurance, focus, or ability with repetitive activity
- Asthenia
  - Generalized weariness or exhaustion in the absence of true weakness
- Non-weakness issues described as weakness
  - Dizziness/Vertigo
  - Imbalance
  - Numbness
  - Ataxia
  - Pain/stiffness
  - Parkinsonism
  - Hypotension
  - Dyspnea on exertion
  - Excessive daytime sleepiness
  - And many more. . .

## Weakness – The Complaint

- True weakness
  - An inability to perform a certain task caused by an inability of the muscle to produce a normal amount of force
- Fatigue
  - A decline in endurance, focus, or ability with repetitive activity
- Asthenia
  - Generalized weariness or exhaustion in the absence of true weakness
- Non-weakness issues described as weakness
  - Dizziness/Vertigo
  - Imbalance
  - Numbness
  - Ataxia
  - Pain/stiffness
  - Parkinsonism
  - Hypotension
  - Dyspnea on exertion
  - Excessive daytime sleepiness
  - And many more. . .

## **Weakness – History**

### **Weakness – Goals of History**

- 1. Differentiate true weakness from fatigue, asthenia, and 'other'
- 2. Begin to localize the problem through anatomic patterns
- 3. Probe for associated features

## **Weakness – History – Differentiating Weakness from Non-Weakness**

- **What do you mean by weakness?**
  - Can immediately change the differential
    - Ex: After standing to walk, my body feels limp and wobbly all over – Consider orthostatic hypotension/presyncope
  
- **Are you physically unable to do certain things or are they simply more effortful?**
  - While not 100%, a general feeling of increased effort may be more suggestive of fatigue

## **Weakness – History – Beginning to Localize**

- **What activities tell you that you are weak?**
  - Starts localization and allows more focused exam
  
- **What happens when you try to perform that activity?**
  - More precise localization through history
  
- Ex:
  - Activities that give trouble:
    - Walking = Possible lower extremity weakness
  - What happens:
    - Right knee buckles = Right quadricep weakness
      - Asymmetric myopathy, right femoral nerve, midlumbar radiculopathy or right knee joint problem

## **Weakness – History – Features to Ask About**

- Diplopia
- Dysarthria
- Dysphagia
  - Choking rather than 'sticking'
- Respiratory distress
  - Sleep disturbance
- Bowel/bladder incontinence
- Falls
- Numbness/tingling, autonomic symptoms
  - Makes certain localizations more likely
- Pain
- Other features
  - Weight loss – Immune, malignancy, nutritional
  - Skin changes – Immune

## **Weakness – Differential and Localization**



## Weakness – Differential Diagnosis

### Disorders that may affect central or peripheral nervous system

- Vascular
  - Ischemic
  - Hemorrhagic
- Trauma/Structural
- Immune
  - Primary neurological immune disease
  - Secondary/Overlap syndromes
- Malignancy
  - Primary neurologic tumor
  - Infiltrative/compressive
  - Paraneoplastic
- Nutritional/metabolic
- Degenerative
- Hereditary

### Disorders that mainly affect peripheral nervous system

- Endocrine
  - Hyper/hypothyroidism
  - Hyperparathyroidism
  - Glucocorticoid excess
- Electrolyte disturbances
  - Hyper/hypokalemia
  - Hypocalcemia
  - Hyper/hypomagnesemia
  - Hypophosphatemia
- Toxic
  - Heavy metals
  - Medications
  - Drugs/alcohol

## Weakness – Potential Initial Work-up

- **Comprehensive metabolic panel**
  - Electrolytes, renal function, hepatic labs
  - Elevated transaminases can indicate muscle disease – Check CK, GGT
- Other electrolytes – Magnesium, Phos
- **Complete Blood Count**
  - Other cause of fatigue/asthenia – anemia
  - Hints to systemic disease/malignancy
- **Muscle enzyme levels**
  - CK – most helpful but not always elevated in muscle disease
  - Aldolase – less specific but can be preferentially elevated in some muscle disease – Anti-synthetase syndrome
- **Serum immunofixation**
  - Signs of immune or hematologic disease
  - IgM kappa paraprotein most common in neuropathies

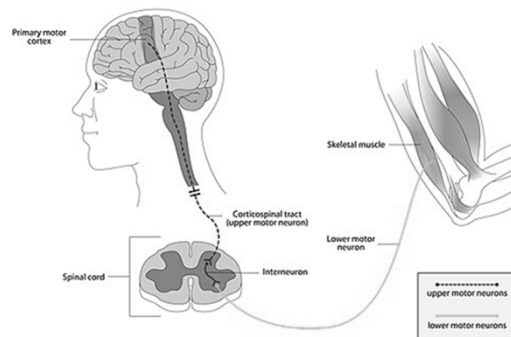
## Weakness – Potential Initial Work-up

- **Endocrine**
  - TSH/T4
  - Other testing per suspicion
- **Vitamin levels**
  - Peripheral nerve – B12, folate, thiamine, pyridoxine
  - Muscle – vitamin E, selenium
  - Spinal cord – B12, copper, vitamin E
- **Immune markers**
  - Screen for rheumatologic disease – ANA/ENA
  - Multifocal disease – ANCA
  - Specific antibodies
    - Muscle – Myositis specific/associated antibodies
    - NMJ – myasthenia gravis antibodies
    - Brain/Spinal cord – MOG, NMO
  - Paraneoplastic
  - ESR/CRP may help to exclude active systemic inflammatory condition
- **Drug levels**
  - Illicit and prescribed

## Weakness – Narrowing Work Up by Localization

### ▪ Central nervous system

- Brain
- Spinal cord



[https://commons.wikimedia.org/wiki/File:Illustration\\_of\\_the\\_motor\\_neuron\\_tract\\_descending\\_from\\_primary\\_motor\\_cortex\\_via\\_spinal\\_cord\\_to\\_skeletal\\_muscle.jpg](https://commons.wikimedia.org/wiki/File:Illustration_of_the_motor_neuron_tract_descending_from_primary_motor_cortex_via_spinal_cord_to_skeletal_muscle.jpg)

### ▪ Peripheral Nervous System

- Alpha motor neurons
- Ventral nerve root
- Plexus/peripheral nerve
- Neuromuscular junction
- Muscle

## Weakness – Localization and Initial Work up Considerations

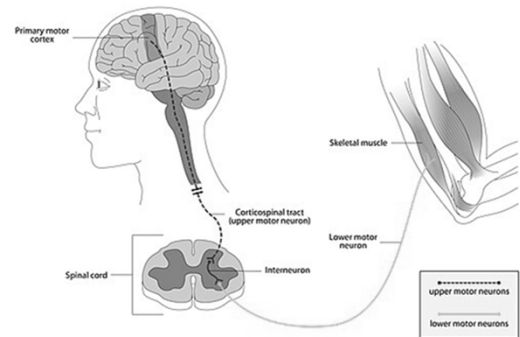
- Central nervous system weakness
- **Imaging**
  - **Brain**
    - **CT**
      - Exclude hemorrhage
      - Often normal in acute ischemic stroke
    - **MRI**
      - Sensitive for acute ischemic stroke
      - Contrast studies for immune and malignant concerns
  - **Spine**
    - **Plain films** – Initial screen for bony abnormalities
    - **CT**
      - Bony structures and hemorrhage
    - **MRI**
      - Visualizes parenchymal and nerve roots
      - Contrast studies for immune and malignant concerns
  - **Vascular imaging**
    - Finding vascular malformations, focal thrombosis
- **Cerebrospinal fluid testing**
  - Most helpful in subacute and progressive causes or to clarify cause of imaging findings

## Weakness – Localization and Initial Work up Considerations

- Peripheral nervous system weakness
  - **Nerve conduction study/EMG**
    - Helps with precise localization
    - Only abnormal in peripheral nervous system involvement
  - **Serum testing**
    - Muscle enzyme levels
      - CK, aldolase
      - Transaminases
    - Neuropathy
      - B12 with MMA
      - Serum immunofixation
      - Diabetes testing – A1c, etc
  - Cerebrospinal fluid testing
    - Specific immune polyradiculopathy/neuropathy
    - Acute onset – Guillain-Barre syndrome and Infectious/immune mimics
    - Subacute to chronic – CIDP and mimics

## Weakness - Localization

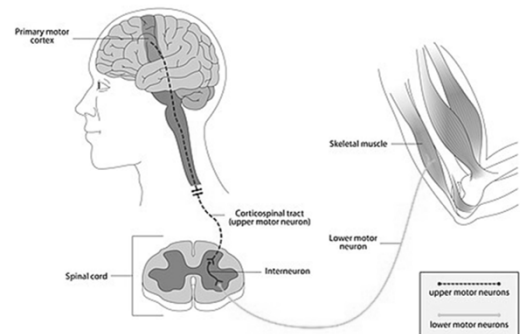
- Central nervous system
  - Brain
  - Spinal cord
- Upper motor neuron
  - Originates in the primary motor cortex
  - Sends descending fiber through the corticospinal tract into the brainstem and spinal cord



[https://commons.wikimedia.org/wiki/File:Illustration\\_of\\_the\\_motor\\_neuron\\_tract\\_descending\\_from\\_primary\\_motor\\_cortex\\_via\\_spinal\\_cord\\_to\\_skeletal\\_muscle.jpg](https://commons.wikimedia.org/wiki/File:Illustration_of_the_motor_neuron_tract_descending_from_primary_motor_cortex_via_spinal_cord_to_skeletal_muscle.jpg)

## Weakness - Localization

- Peripheral nervous system – motor pathway
  - Alpha motor neurons
    - Lower motor neuron
    - Reside in cranial nerve nuclei (brainstem) and anterior horn (spinal cord)
    - Send axons that ultimately connect directly to the muscle
  - Cranial nerves
  - Ventral nerve root
  - Plexus/peripheral nerve
  - Neuromuscular junction
  - Muscle




[https://commons.wikimedia.org/wiki/File:Illustration\\_of\\_the\\_motor\\_neuron\\_tract\\_descending\\_from\\_primary\\_motor\\_cortex\\_via\\_spinal\\_cord\\_to\\_skeletal\\_muscle.jpg](https://commons.wikimedia.org/wiki/File:Illustration_of_the_motor_neuron_tract_descending_from_primary_motor_cortex_via_spinal_cord_to_skeletal_muscle.jpg)

## Weakness – Localization – Central v. Peripheral

- **Central Nervous System**


- Brain
- Spinal cord



*Upper motor  
neuron signs*

- **Peripheral Nervous System**

- Cranial nerves
- Anterior horn cell
- Nerve roots
- Plexus
- Peripheral Nerve
- Neuromuscular junction
- Muscle



*Lower motor  
neuron signs*

<b>Sign/Symptom</b>	<b>Central Nervous System - Upper Motor Neuron Signs</b>	<b>Peripheral Nervous System - Lower Motor Neuron Signs</b>
<b>Reflexes</b>	Increased Below the lesion	Decreased In affected areas
<b>Muscle Atrophy</b>	No	Yes (chronically)
<b>Muscle Tone</b>	Increased (chronically)	Decreased or Normal
<b>Fasciculations</b>	No	Yes
<b>Plantar Response</b>	Upgoing	Downgoing
<b>Pain</b>	Less common	More common

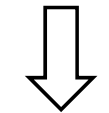
Sign/Symptom	Upper Motor Neuron Lesion	Lower Motor Neuron Lesion
<b>Facial weakness – When present</b>	Sparing of forehead wrinkle and able to fully close eyes	Unable to wrinkle forehead, unable to close eyes fully
<b>Extremity weakness</b>	Upper extremity – Affects Extensors > Flexors  Lower extremity – Affects Flexors > Extensors	Dependent on localization

Localization	Pattern of Weakness	Other Features
<b>Hemisphere - Cerebral cortex</b>	Unilateral f/a/l or subset	Cortical signs – Aphasia, Apraxia, Neglect; +/- hemisensory loss
<b>Hemisphere - Subcortical</b>	Unilateral f/a/l or subset	+/- hemisensory loss, dysarthria
<b>Brainstem</b>	Unilateral a/l and contralateral CN	+/- hemisensory loss
<b>Cervical cord</b>	Unilateral UE, Paraparesis, or tetraparesis	+/- unilateral or bilateral sensory loss; +/- bowel/bladder changes
<b>Thoracic cord</b>	Unilateral LE or paraparesis	+/- unilateral or bilateral sensory loss; +/- bowel/bladder changes
<b>Lumbosacral cord</b>	Unilateral LE or paraparesis	+/- unilateral or bilateral sensory loss; +/- bowel/bladder changes

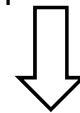
File:Gray764.png - Wikimedia Commons

## Upper motor neuron findings on exam

- Weakness on one side of the body
- Facial weakness
- Other symptoms such as dysarthria, dysphagia, aphasia
- Bilateral weakness
- Lesion is located anywhere above the patient's symptoms or 'pin-level' if present
- Can have LMN features (atrophy, fasciculations, etc) at the level of the lesion



Brain

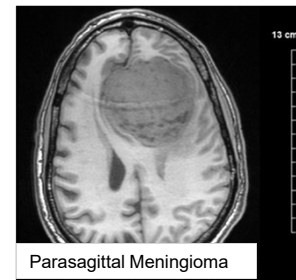


Spinal cord

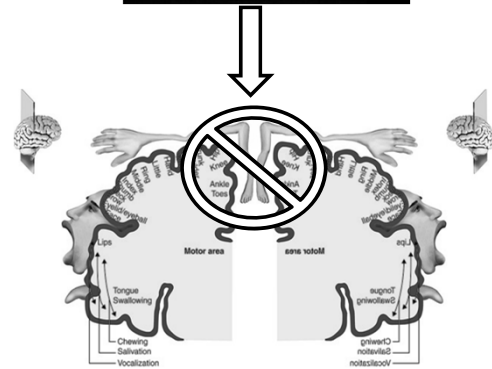
## Exceptions to the 'Rules'

Brain lesions that cause bilateral weakness

- Bilateral, multifocal, multiple lesions cloud the picture
  - Classic for disorders like multiple sclerosis
- Bilateral weakness from brain lesions
  - Bilateral watershed infarcts from hypotension
    - Bilateral proximal upper and lower extremity weakness – 'man in a barrel' syndrome
  - Bilateral medial frontal lesions
    - Bilateral ACA stroke, parasagittal mass
- Acute spinal lesions can have decreased reflexes and tone for days to weeks following initial onset – Spinal shock
- Any lesion only affecting one half of the spinal cord
  - Brown-Sequard syndrome: weakness, reduced vibration/proprioception ipsilateral to the lesion and reduced pinprick sensation contralateral to the lesion.
- High cervical lesions may involve the spinal trigeminal nucleus and can cause facial numbness but NOT weakness.



Parasagittal Meningioma



File:Huge Meningioma.jpg - Wikimedia Commons

File:Anatomytool Sensory homunculus English.jpg - Wikimedia Commons

# Cases

## Case Presentation 1

64-year-old man with sudden onset of right upper extremity weakness two weeks ago.

Two weeks ago, he was sitting and drinking a beer and noticed that his right arm felt weak. This was noticeable but mild, so he went to bed. The next morning was unable to move his hand at all, so he went to the emergency room.

In the emergency room, CT of the brain was 'unremarkable,' so he was sent home. Since then it has gotten a little better—now he is able to grip a little bit. Denies numbness and pain. Denies other symptoms.



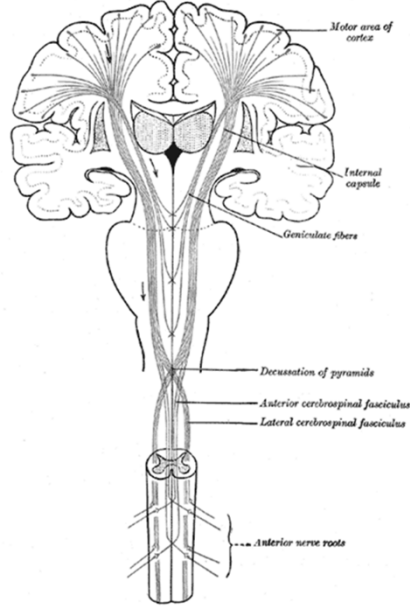
## Examination

- Mental status, language, cranial nerves, sensation, coordination, and gait all normal
- Motor exam:
  - Bulk and tone are normal.
  - 5/5 strength throughout except for 4+/5 strength in his proximal right arm and 2/5 strength in his right hand.
  - There is right pronator drift.
- Reflexes: 2+ in the right biceps, otherwise 1+ on the right and left arms. 0 in the knees and ankles.

## Examination

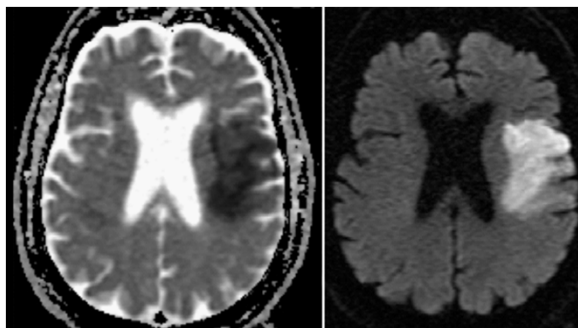
- Mental status, language, cranial nerves, sensation, coordination, and gait all normal
- Motor exam:
  - Bulk and tone are normal.
  - 5/5 strength throughout except for 4+/5 strength in his proximal right arm and 2/5 strength in his right hand.
  - There is right pronator drift.
- Reflexes: 2+ in the right biceps, otherwise 1+ on the right and left arms. 0 in the knees and ankles.

Unilateral arm weakness with hyperreflexia

	Localization	Pattern of Weakness	Other Features
 <p>Motor area of cortex Internal capsule Geniculate fibers Decussation of pyramids Anterior cerebrospinal fasciculus Lateral cerebrospinal fasciculus Anterior nerve roots</p> <p>File:Gray764.png - Wikimedia Commons</p>	<b>Hemisphere - Cerebral cortex</b>	Unilateral f/a/l or subset	Cortical signs – Aphasia, Apraxia, Neglect; +/- hemisensory loss
	<b>Hemisphere - Subcortical</b>	Unilateral f/a/l or subset	+/- hemisensory loss, dysarthria
	<b>Brainstem</b>	Unilateral a/l and contralateral CN	+/- hemisensory loss
	<b>Cervical cord</b>	Unilateral UE, Paraparesis, or tetraparesis	+/- unilateral or bilateral sensory loss; +/- bowel/bladder changes
	<b>Thoracic cord</b>	Unilateral LE or paraparesis	+/- unilateral or bilateral sensory loss; +/- bowel/bladder changes
	<b>Lumbosacral cord</b>	Unilateral LE or paraparesis	+/- unilateral or bilateral sensory loss; +/- bowel/bladder changes

## Work-up

- MRI Brain without contrast: a small acute ischemic cortical infarct is noted in the left precentral gyrus.
- Followed by a stroke work-up and management of risk factors.



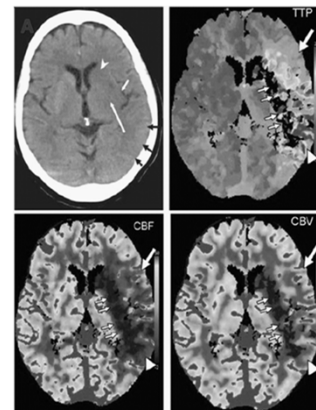
File:DWE MRI of cerebral infarction.png - Wikimedia Commons

## Clues to Stroke Diagnosis

- Sudden onset of symptoms
  - Vascular causes likely
- Weakness on only one side of the body
- Painless
  - Spinal cord slightly less likely
- Weakness was in no clear nerve root or nerve distribution
  - Spinal cord less likely
- Relatively increased reflexes in the area of weakness

## Why was the CT of the brain negative?

- Acute ischemic stroke and small strokes often have normal CT
- The CT scan was done soon after symptom onset– strokes become more clear on CT 6-12 hours after symptom onset
  - CT perfusion can increase sensitivity
- Also note that the CT does a very poor job of imaging the brainstem (not relevant in this case)



File:CT and MR perfusion of cerebral infarction.png - Wikimedia Commons

## Case Presentation 2

52-year-old man with several years of difficulty walking, specifically because of right leg weakness. This problem has been slowly getting worse over time. Two years into symptoms he notes new right foot numbness.

He said that he will trip and has to drag his right leg. He also has to drive with two feet because he can't move his right leg from one pedal to the other. Denies bowel/bladder problems. No pain.

## Examination

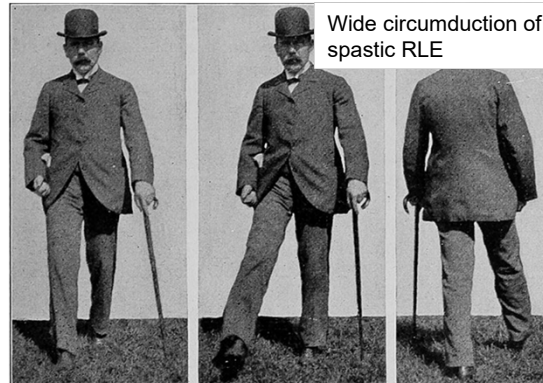
- Mental status and Cranial nerves normal
- Motor: 5/5 strength in both upper extremities and in the left lower extremity. In the right lower extremity he had 2/5 hip flexion, 4/5 knee extension, 2/5 knee flexion, 4/5 dorsiflexion and 4+/5 plantar flexion.

- Reflexes:

	Right	Left
Biceps	3	2
Triceps	1	1
Brachioradialis	2	1
Patella	3	2
Achilles	2	1
Plantar response	Upgoing	Mute

## Examination

- Sensory: Decreased in the right leg to pinprick and vibration compared to the left otherwise normal.
- Coordination: normal
- Gait: spastic in the right lower extremity



File:Nervous and mental diseases (1908) (14591322220).jpg - Wikimedia Commons

## Examination

- Mental status and Cranial nerves normal
- Motor: 5/5 strength in both upper extremities and in the left lower extremity. In the right lower extremity he had 2/5 hip flexion, 4/5 knee extension, 2/5 knee flexion, 4/5 dorsiflexion and 4+/5 plantar flexion.

- Reflexes:

	Right	Left
Biceps	3	2
Triceps	1	1
Brachioradialis	2	1
Patella	3	2
Achilles	2	1
Plantar response	Upgoing	Mute

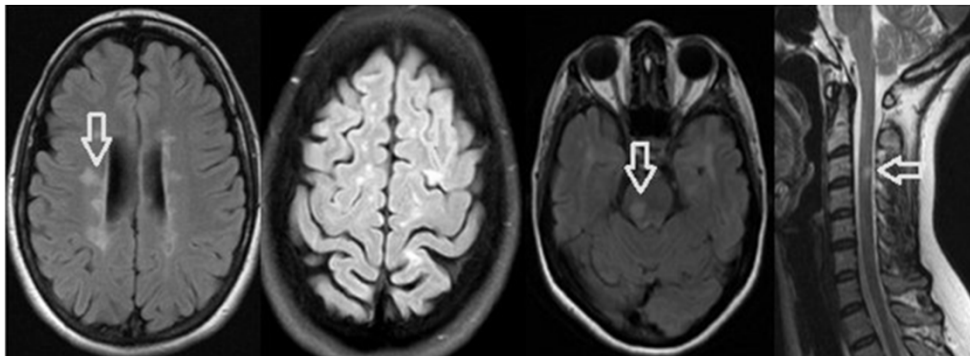
Chronic, progressive unilateral lower extremity weakness, hyperreflexia, and sensory loss

## Previous testing done prior to referral

- MRI Hip: mild bilateral hip joint osteoarthritis
- EMG/NCS: Normal
- MRI Lumbar spine without contrast: mild disc bulging diffusely. Mild to moderate foraminal narrowing throughout.
- CT of the brain unremarkable

## Diagnostic work-up

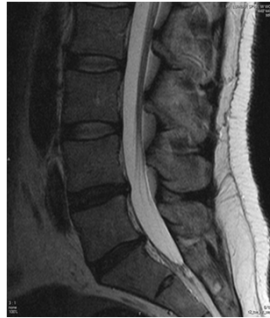- MRI of the brain, cervical and thoracic spinal cord with and without contrast
  - Multifocal T2 hyperintensities through the brain and spinal cord
  - Diagnosed with primary progressive multiple sclerosis



File:Diseminacion en espacio.jpg - Wikimedia Commons

## Clues to localization

- Clear upper motor neuron signs and painless!
  - EMG/NCS only helpful in lower motor neuron causes of weakness
  - MRI of the lumbar spine mostly visualizes cauda equina rather than the spinal cord
- Unilateral weakness without Brown-Sequard pattern (contralateral sensory loss) most suggestive of brain lesion. However, unusual pattern for a brain lesion so imaging at every level above the area of weakness.



File:Lumbar MRI t2-tse-rst-sagittal 06.jpg - Wikimedia Commons

## Case Presentation 3

71-year-old man with 2 years of worsening gait problems.

He reports that his legs felt “wobbly” as if they were going to buckle while walking. When asked about numbness or tingling, he said that he had noticed some numbness in his feet over the same time period. Denied any other symptoms.

## Examination

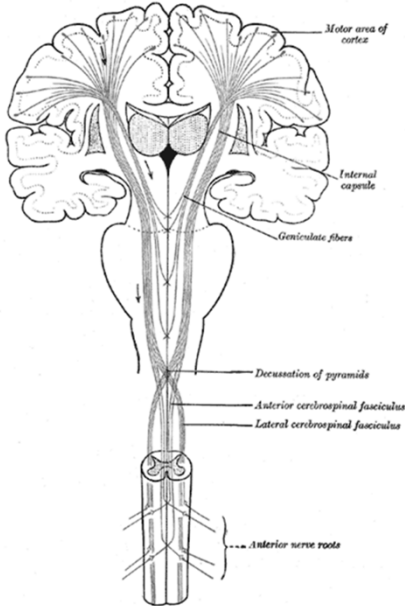
- Mental Status: normal
- Cranial nerves: normal
- Motor exam: Normal with the exception of 4+/5 hip flexor weakness bilaterally. Tone mildly increased in the legs.
- Reflexes: 3+ throughout with bilateral upgoing toes
- Sensation: decreased vibratory and pinprick sensation in his hands and feet without a clear 'pin-level'
- Coordination: normal
- Gait: normal

## Examination

- Mental Status: normal
- Cranial nerves: normal
- Motor exam: Normal with the exception of 4+/5 hip flexor weakness bilaterally. Tone mildly increased in the legs.
- Reflexes: 3+ throughout with bilateral upgoing toes
- Sensation: decreased vibratory and pinprick sensation in his hands and feet without a clear 'pin-level'
- Coordination: normal
- Gait: normal

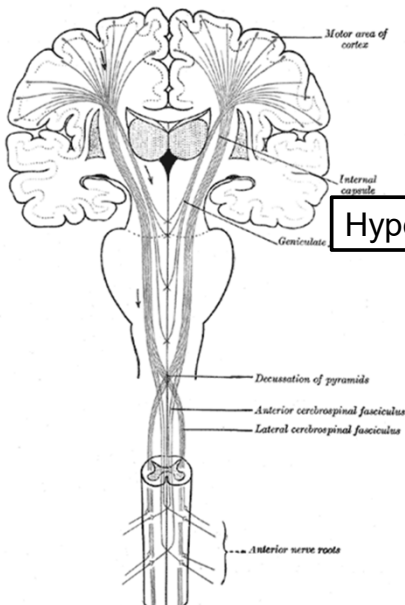
Chronic, progressive bilateral lower extremity weakness, hyperreflexia, and sensory loss





File:Gray764.png - Wikimedia Commons

Localization	Pattern of Weakness	Other Features
<b>Hemisphere - Cerebral cortex</b>	Unilateral f/a/l or subset	Cortical signs – Aphasia, Apraxia, Neglect; +/- hemisensory loss
<b>Hemisphere - Subcortical</b>	Unilateral f/a/l or subset	+/- hemisensory loss, dysarthria
<b>Brainstem</b>	Unilateral a/l and contralateral CN	+/- hemisensory loss
<b>Cervical cord</b>	Unilateral UE, Paraparesis, or tetraparesis	+/- unilateral or bilateral sensory loss; +/- bowel/bladder changes
<b>Thoracic cord</b>	Unilateral LE or paraparesis	+/- unilateral or bilateral sensory loss; +/- bowel/bladder changes
<b>Lumbosacral cord</b>	Unilateral LE or paraparesis	+/- unilateral or bilateral sensory loss; +/- bowel/bladder changes

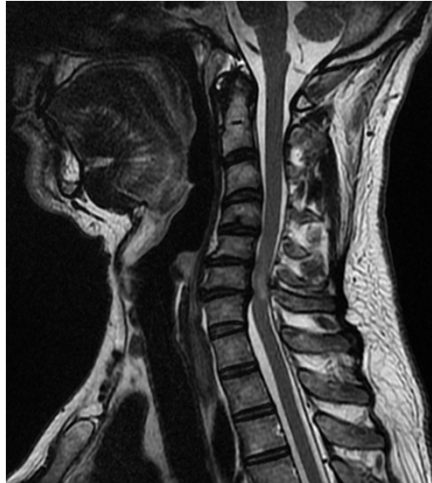

File:Gray764.png - Wikimedia Commons

Localization	Pattern of Weakness	Other Features
<b>Hemisphere - Cerebral cortex</b>	Unilateral f/a/l or subset	Cortical signs – Aphasia, Apraxia, Neglect; +/- hemisensory loss
<b>Hemisphere - Subcortical</b>	Unilateral f/a/l or subset	+/- hemisensory loss, dysarthria
<b>Hyperreflexia in the upper extremities points toward the C-spine</b>		
<b>Cervical cord</b>	Unilateral UE, Paraparesis, or tetraparesis	+/- unilateral or bilateral sensory loss; +/- bowel/bladder changes
<b>Thoracic cord</b>	Unilateral LE or paraparesis	+/- unilateral or bilateral sensory loss; +/- bowel/bladder changes
<b>Lumbosacral cord</b>	Unilateral LE or paraparesis	+/- unilateral or bilateral sensory loss; +/- bowel/bladder changes

## Work-up

- MRI Cervical and thoracic spine without contrast showed spondylotic changes in the cervical spine causing severe cervical stenosis



File:Compressive myelopathy C6C7.png - Wikimedia Commons

## Clues to localization and diagnosis

- *Bilateral weakness with upper motor neuron signs that was painless so most likely spinal cord localization*
- Interestingly, his deficits could have been mostly due to sensory loss
- A thoracic lesion may be suggested by the lack of arm weakness BUT
  - The patient had sensory changes in his hands that would not be explained by a thoracic lesion
  - **Cervical** spondylotic myelopathy is more common! It is the most common cause of spinal cord dysfunction worldwide in patients older than 55 years old.
  - It is common for cervical lesions like this to cause more symptoms in the lower extremities than in the upper extremities

## Recap

- Weakness is decreased muscle force from a lesion in the motor pathway
  - Differentiate from mimics – fatigue, asthenia, and ‘other’
- Weakness can be divided into
  - Central nervous system – Upper motor neuron
  - Peripheral nervous system – Lower motor neuron
- Imaging is often one of the most important tools for diagnosis of a central nervous system cause of weakness
  - MRIs are far superior to CTs for imaging the nervous system parenchyma
  - Lumbar spine MRI do not significantly image the spinal cord
- The lesion can be anywhere above the level of weakness/clinical symptoms

## References

- Cho & Bhattacharyya. 2018. **Approach to Myelopathy**. *Continuum*. 24 (2) 386-406.
- Larson & Wilbur. 2020. **Muscle Weakness in Adults: Evaluation and Differential Diagnosis**. *AAFP*. 101 (2) 95-108.
- Shulman & Abdalkader. 2023. **Imaging of Central Nervous System Ischemia**. *Continuum*. 29 (1) 54-72.



# Evaluation of Weakness

**Michael Isfort, MD**

*Assistant Professor - Clinical  
Department of Neurology  
Neuromuscular Division*

*The Ohio State University Wexner Medical Center*

**MedNet21**  
Center for Continuing Medical Education

 **THE OHIO STATE UNIVERSITY**  
WEXNER MEDICAL CENTER

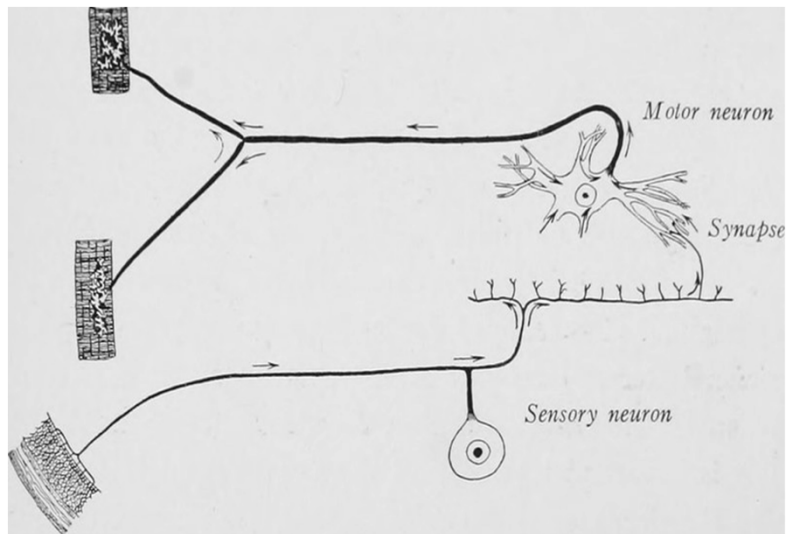
## Part II – Peripheral Nervous System (PNS)

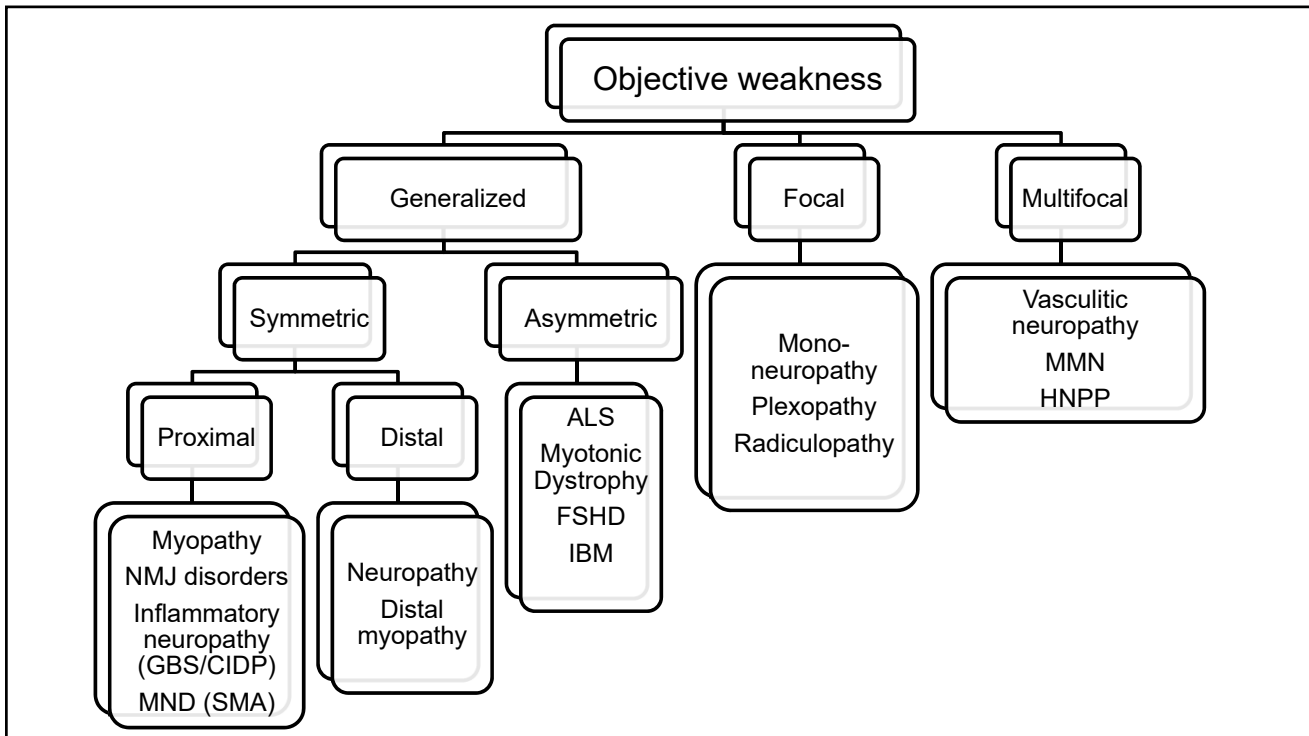
## Objectives

- Review components of the peripheral nervous system
- Review patterns of weakness and discuss how this can narrow the differential
- Discuss evaluation modalities
- Review cases of common and uncommon causes of PNS weakness

## PNS Anatomy

- Cranial nerves
- Spinal nerves and dorsal root ganglia
- Motor neuron
- Plexus
- Peripheral Nerves
- Muscle
- Neuromuscular junction





## Localization

- **Anterior horn cell** - *motor only*, LMN weakness / reflex loss
- **Nerve root (radiculopathy)** - *usually painful*, motor / sensory / reflex loss in dermatomal distribution
- **Plexus (i.e. plexopathy)** – *usually one limb*, multiple nerve root distributions
- **Peripheral nerve** – *often length dependent, symmetric*, motor / sensory / reflex loss.
- **Neuromuscular junction** – *fatigable weakness (MG)* or improvement with exercise (LEMS), no sensory
- **Muscle (myopathy)** - *motor only*, usually proximal > distal weakness

## Evaluation: History

- Age at onset:
  - Birth vs. childhood vs. adulthood
- Evolution of symptoms
  - Acute/sub-acute vs. Chronic
  - Static vs. Episodic
- Associated features:
  - Myalgia/cramping
  - Atrophy
  - Ocular
  - Skin changes
- PMHX
  - Thyroid, parathyroid, adrenal, cancer, HIV, diabetes, kidney disease
  - Rheumatologic disease
  - Cardiac (cardiomyopathy or conduction)
  - Pulmonary
  - Musculoskeletal (scoliosis, joint/foot deformity)
  - Rhabdomyolysis/malignant hyperthermia
- FH
  - X-linked, AD, AR, maternal transmission
- SH
  - Smoking >>paraneoplastic
  - Alcohol
- Meds
  - Statins
  - Amiodarone, chloroquine, colchicine, prednisone

## Evaluation: Physical Exam

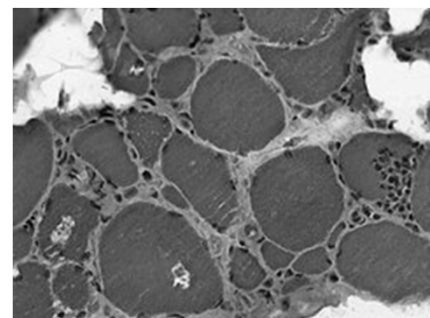
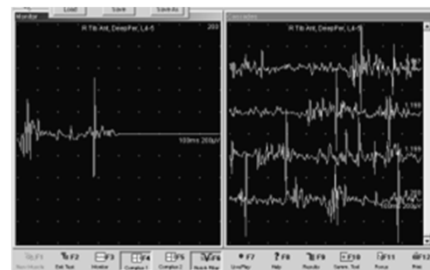
- Strength (MMT)
  - Atrophy
  - Appropriate positioning especially neck flexion
  - Fasciculations
- Reflexes
- Cranial Nerves
- Gait
- Sensory
  - Large and small fiber
  - Distribution
- Myotonia: Percussion/clinical
- Scoliosis
- Cardiac exam
- Respiratory exam
- Skin exam

## Evaluation: Labs

- CK
- Myasthenia Gravis Panel:
  - Acetylcholine Receptor
  - MuSK
  - LRP4
- Muscle Specific/Muscle Associated Antibodies
  - Can be associated with dermatomyositis/antisynthetase syndromes
  - HMGCR Abs - IMNM
  - NT5C1a antibodies – sIBM
- ANA/Rheumatologic Screen
- Neuropathy evaluation
  - HgA1c/GTT
  - B12/MMA
  - Monoclonal screen
  - Many other additional labs based on specific clinical cases
- Genetic Testing
  - Disease specific
  - NGS panels

## Evaluation: Additional Testing

- EMG/NCS – Electrodiagnostic Testing
  - Differentiate myogenic vs neurogenic
  - RNS and SFEMG can evaluate the neuromuscular junction
- Muscle/Nerve Biopsy
  - Aim to take muscle from a clinically weak/affected muscle.
  - Muscle Bx: Distinguish myopathy from neurogenic disease vs specific diagnosis
  - Nerve biopsy reserved for certain pathologies

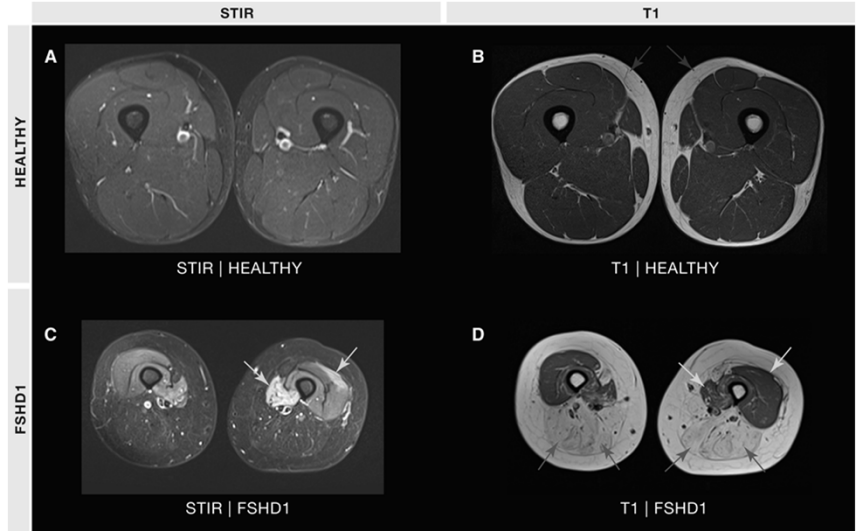


[https://commons.wikimedia.org/wiki/File:IBM\\_rimmed\\_vacuoles\\_HE\\_x200.jpg](https://commons.wikimedia.org/wiki/File:IBM_rimmed_vacuoles_HE_x200.jpg)

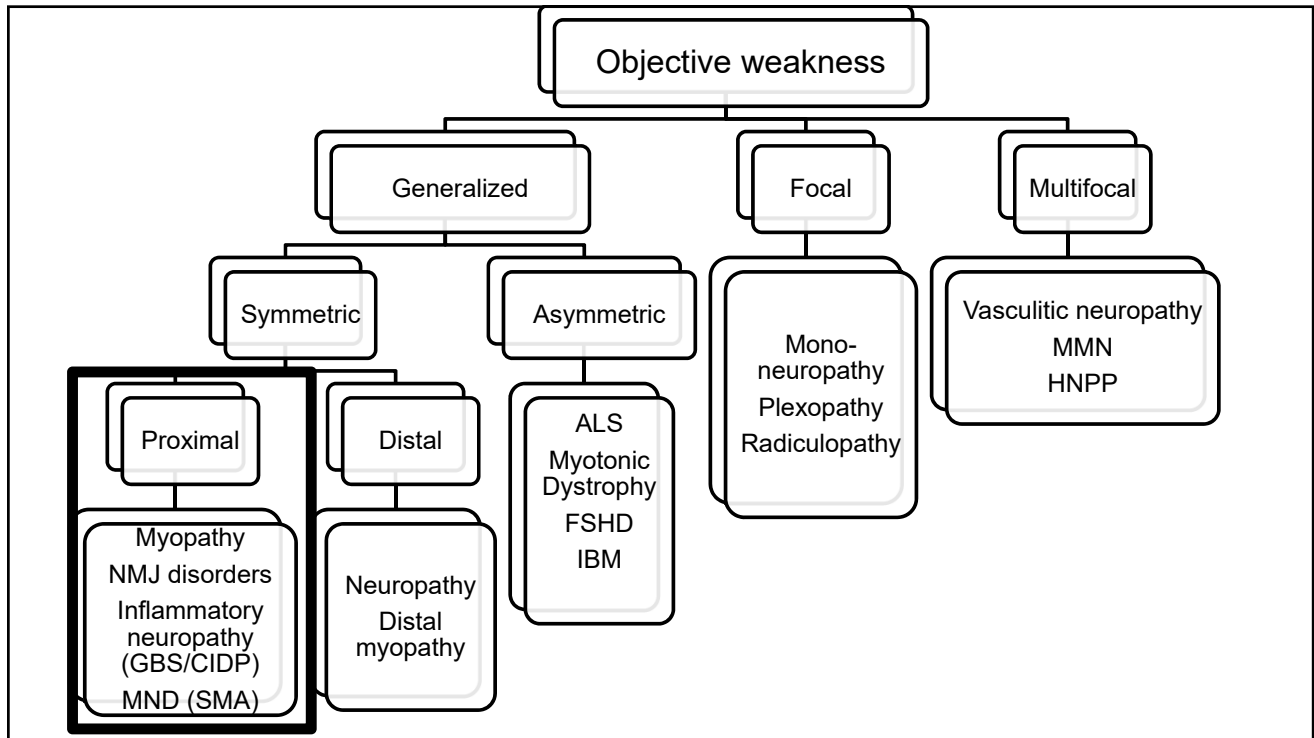


# Evaluation: Muscle/Nerve Imaging

- Neuromuscular Ultrasound
- Muscle MRI
- MR Neurography

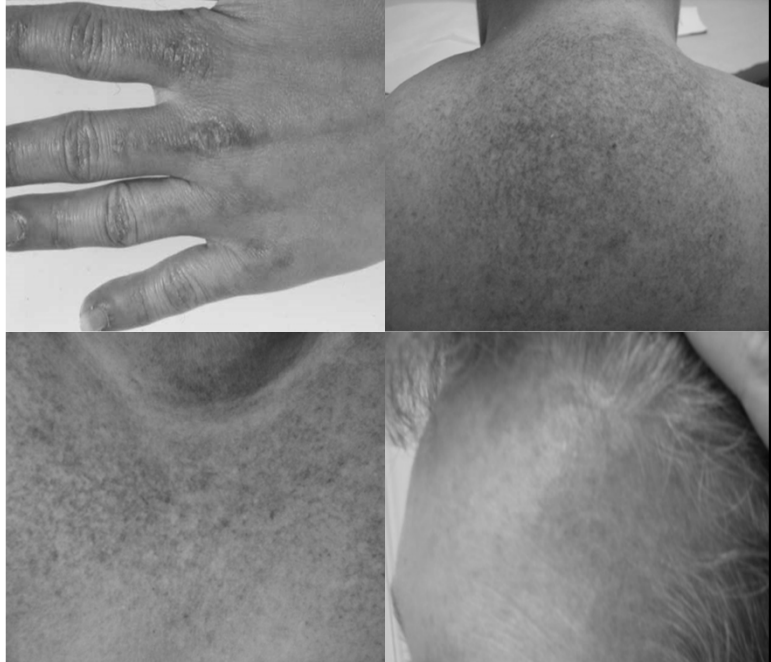

[https://upload.wikimedia.org/wikipedia/commons/8/83/FSHD\\_Muscle\\_MRI\\_T1\\_and\\_T2.png](https://upload.wikimedia.org/wikipedia/commons/8/83/FSHD_Muscle_MRI_T1_and_T2.png)  
(no changes made)



## Vignette

- 45 y/o WF
  - Weakness
    - Difficulty going up steps
  - Facial and knuckles rash
  - Swelling around the eyes
  - Difficulty swallowing
  - History of ovarian cancer
  - CK normal
  - EMG/NCS: Proximal, irritable myopathic changes

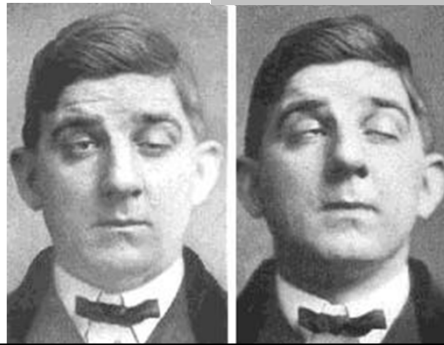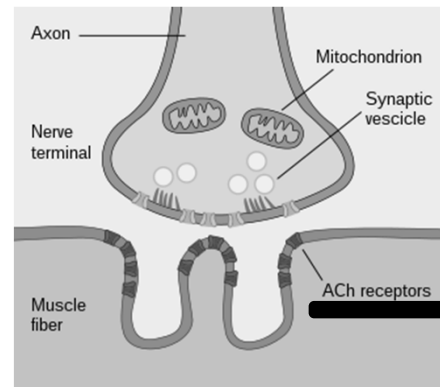


## Dermatomyositis

- Clinical Features:
  - Subacute or insidious onset
  - Gradual worsening
  - Symmetric proximal weakness
  - Multisystem disease (Skin & Muscle)
    - Skin manifestations precede muscle weakness in 50-60%
  - CK elevation (normal in 10%)
- Characteristic histopathology on muscle biopsy
- Risk of malignancy
- Associated Antibodies
  - Mi-2, TIF1-gamma, NXP-2, MDA-5, SAE
- Treatment with immunosuppression/immunomodulation

# Myasthenia Gravis

- Post-synaptic neuromuscular junction disorder
- Clinical Features
  - Fatigable weakness
  - Ocular symptoms – ptosis, diplopia
  - Bulbar
  - Facial muscle weakness
  - Dysphagia
  - Difficulty chewing
    - Painless
  - Proximal muscle weakness

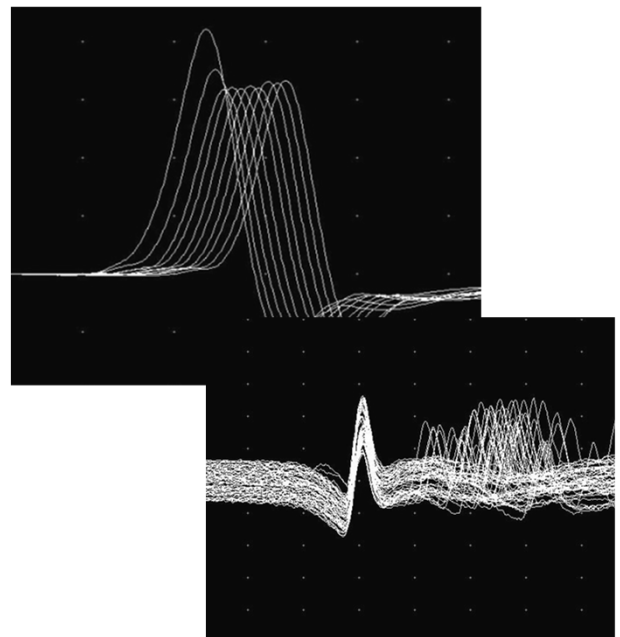


[https://commons.wikimedia.org/wiki/File:Neuromuscular\\_junction.svg](https://commons.wikimedia.org/wiki/File:Neuromuscular_junction.svg)

Posey & Spiller, public domain, authors are both more than 70 years death.

## Myasthenia Gravis: Diagnosis

- Serology
  - AchR (binding antibodies) (80-90%)
  - MuSK (~10%)
  - LRP4 (~1%)
- Ice Pack test
- Electrodiagnostic testing:
  - RNS
  - SFEMG
- Radiology
  - CT or MRI chest (Thymoma)



## Myasthenia Gravis: Treatment

- Symptomatic treatment
  - Acetylcholine esterase inhibitors
- Thymectomy
  - If thymoma present
  - Generalized, AChR positive, <65 yo
- Immunosuppressive/Immunomodulatory
  - Prednisone
  - Azathioprine/mycophenolate
  - Complement inhibitors
  - FcRn inhibitors

## Lambert Eaton Myasthenic Syndrome (LEMS)

- Presynaptic Neuromuscular Junction Disorder
- **Clinical Features:**
  - Weakness of proximal limb muscles
    - Chronic, fluctuating
    - Some improvement in power with brief exercise
    - Patients report myalgia and muscle stiffness
  - Bulbar weakness
  - Autonomic symptoms
    - Dry mouth, erectile dysfunction, constipation
    - Orthostatic intolerance, urination difficulty, dry eyes
  - Absent or hypoactive reflexes on examination
    - Post exercise facilitation

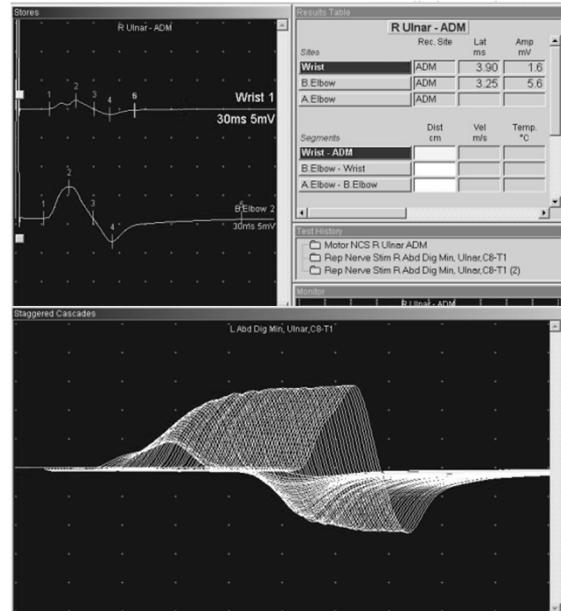
## Lambert Eaton Myasthenic Syndrome (LEMS)

### • Diagnosis:

- Serology: Voltage Gated Calcium channel (P/Q) antibodies
- Ct Chest (Paraneoplastic disorder (~2/3))
  - 90% small cell lung cancer
- EDX
  - Post-exercise facilitation
  - Increment on fast repetitive nerve stimulation

### • Treatment:

- Symptomatic: 3'4-DAP
- Paraneoplastic: Treat malignancy
- Autoimmune: Immunosuppression

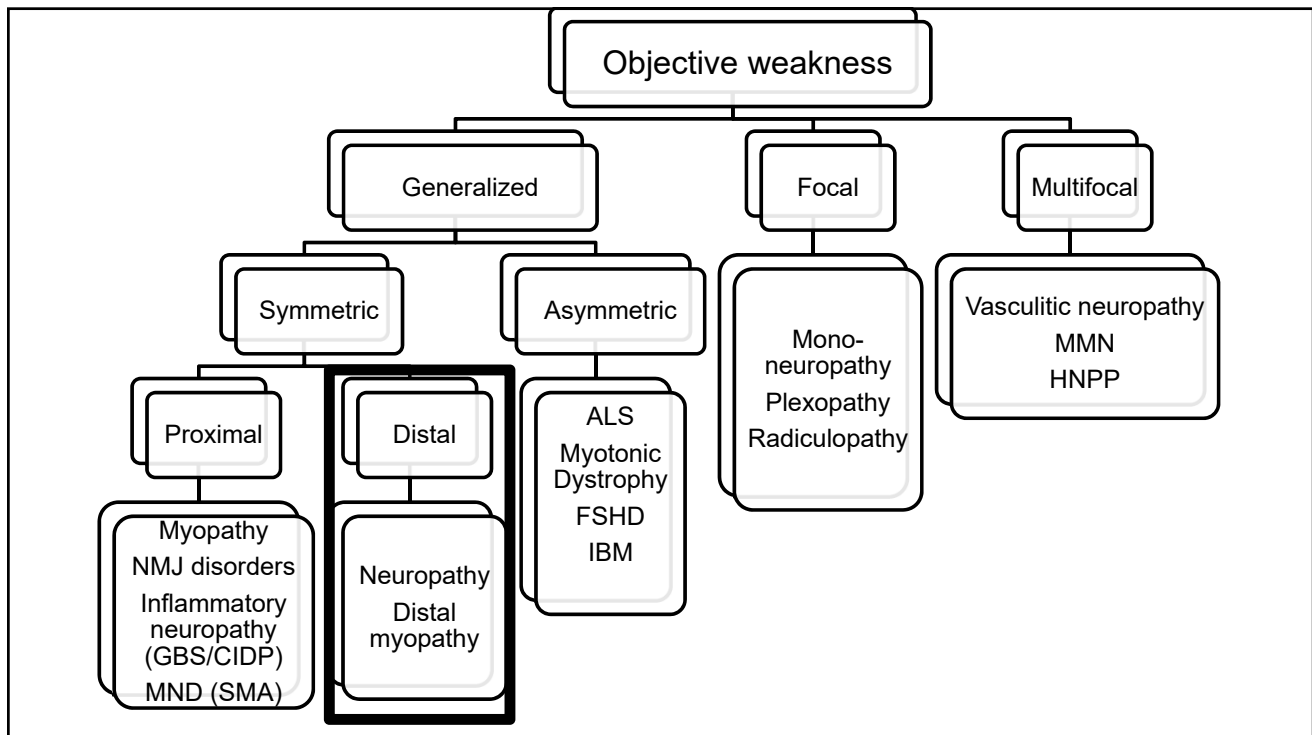
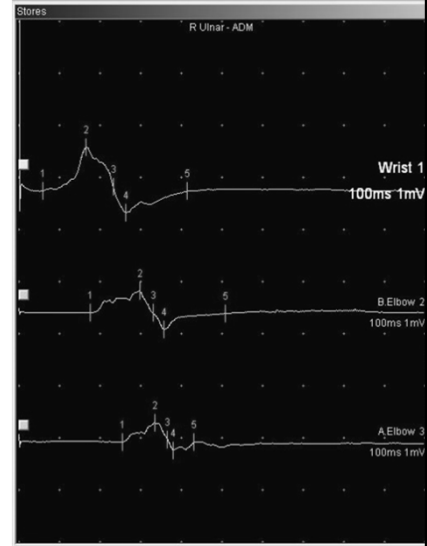


## Vignette

- 38 year old AA female
- *PMH* Hodgkin's lymphoma 1996 s/p MOPP/ABVD in remission
- Two months history of
  - Fatigue; tiredness
  - Numbness and tingling (*feet-> legs to the thigh*)
  - progressive weakness (Non-ambulatory)
- Diagnosed with GBS and received IVIG treatment with improved
- Recurrence after one month
  - Improved after second course of IVIG
- Examination
  - Motor:
    - SA 4-, EF/EE 5, WE 4+, WF 4, IH 4, HF 3-, KE 4, ADF 2, APF 4
  - DTR absent
  - Distal sensory gradient to pinprick & vibration
- Workup:
  - EMG/NCS with non-length dependent demyelinating neuropathy
  - CSF: Elevated protein with normal WBC
- Diagnosis?

# Chronic Inflammatory Demyelinating Polyradiculoneuropathy (CIDP)

- **Clinical Features**
  - Progressive or relapsing, symmetric, proximal and distal weakness and sensory involvement
  - >8 weeks of progression
  - Absent or reduced reflexes
- Electrodiagnostic studies can be helpful in identifying sensorimotor neuropathy and establishing primary demyelinating pathology.
- **Supportive features:**
  - Albuminocytologic dissociation in CSF : Elevated protein without elected cell count (<5-10 cells/mm<sup>3</sup>)
  - Nerve enlargement on ultrasound
  - Nerve root enlargement or enhancement on MRI
  - Response to treatment
- **Treatment**
  - Corticosteroids
  - IVIG/PLEX
  - Steroid sparing immunosuppressants.



## Distal Symmetric Weakness Pattern

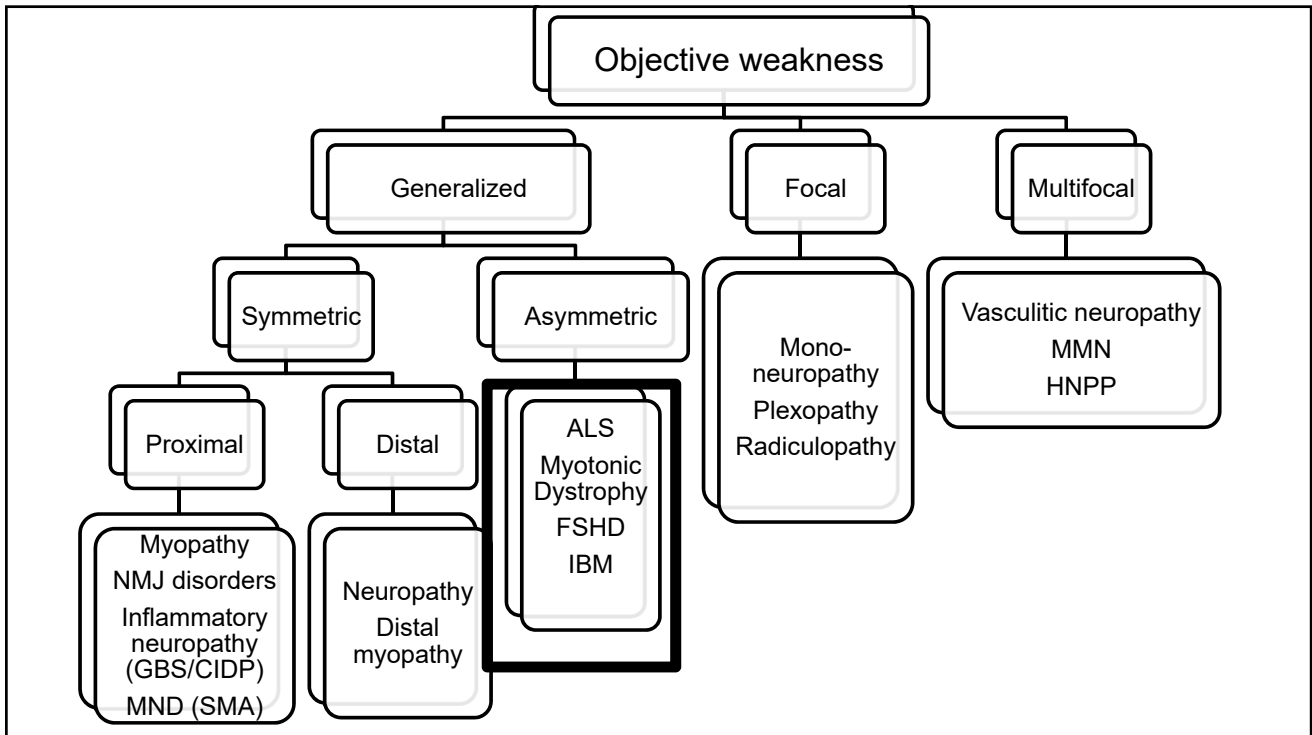
- Sensory examination –abnormal
  - Peripheral neuropathy
- Sensory examination –normal
  - Distal myopathy
  - Motor neuropathies

## Vignette

- 23 y/o man
  - Difficulty running and toe walking since age 3
  - No arm weakness or sensory symptoms
  - FH: Pos. with male to male transmission
  - Weak ankle dorsiflexor and big toe extensor
  - CK: Normal
  - EMG: Myopathic

### Distal myopathies

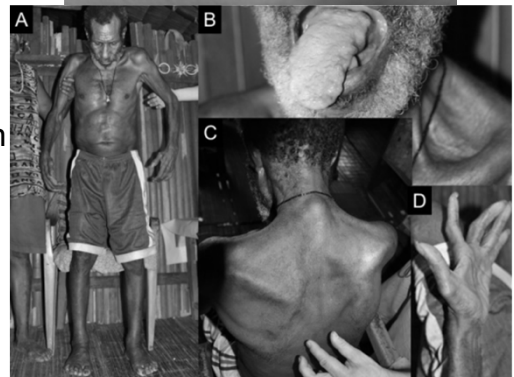
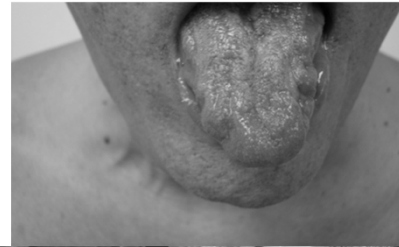Disease	Gene	Age at onset	Initial muscles	CK	Muscle Bx
Welander	2p 13	> 40	Finger and wrist extensors	1-4 X	Rimmed vacuoles
Udd	TTN	>35	Anterior leg compartment	1-4X	± Rimmed vacuoles
Markesbery-Griggs	ZASP	>40	Anterior leg compartment	1-3X	Vacuolar & myofibrillar
Distal myotilinopathy	MYOT	> 40	Posterior > anterior leg	1-3X	Vacuolar & myofibrillar
Laing (MPD1)	MYH 7	< 20	Anterior leg & neck flexors	1-3X	Type 1 fiber atrophy
Vocal cord & pharyngeal (MPD2)	MATR3	35-60	Asymmetric lower leg and hand; dysphonia	1-8 X	Rimmed vacuoles
New Finnish (MPD3)	8 p22-q11 12 q13-22	>30	Hands or anterior leg	1-4 X	Dystrophic; rimmed vacuoles
Nonaka	GNE	15-20	Anterior leg compartment	< 10 times	Rimmed vacuoles
Miyoshi	DYSF	15-30	Posterior leg compartment	> 10 times	Myopathic





## Amyotrophic Lateral Sclerosis-ALS

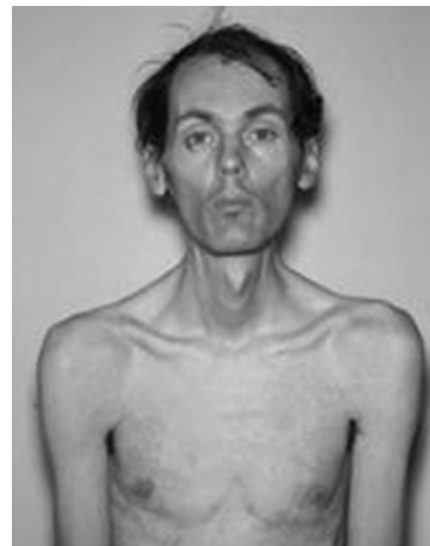- ALS is characterized by combination of upper and lower motor neuron dysfunction.
- Clinical Features:
  - Weakness
  - Muscle atrophy
  - Upper motor neuron findings (hyper-reflexia, increased tone)
  - Cramps
  - Fasciculations
  - Dysphagia
  - Dysarthria
  - Pseudobulbar affect
  - Restrictive lung disease
- Diagnosis: Predominantly clinical. EMG/NCS can help confirm active and chronic neurogenic changes
  - About 10% genetic, can perform genetic testing
- Treatment:
  - Riluzole – Prolongs life 2-3 months
  - Edaravone – Slows progression by ~1/3
  - Sodium Phenylbutyrate-Taurursodiol



[https://commons.wikimedia.org/wiki/File:ALS\\_clinical\\_picture.png](https://commons.wikimedia.org/wiki/File:ALS_clinical_picture.png). No changes made.

## Vignette

- 42 year old female
- Stiffness of the hands x 5 years
- Swallowing difficulty
- Cataract surgery age 20
- Pacemaker
- Excess daytime sleepiness



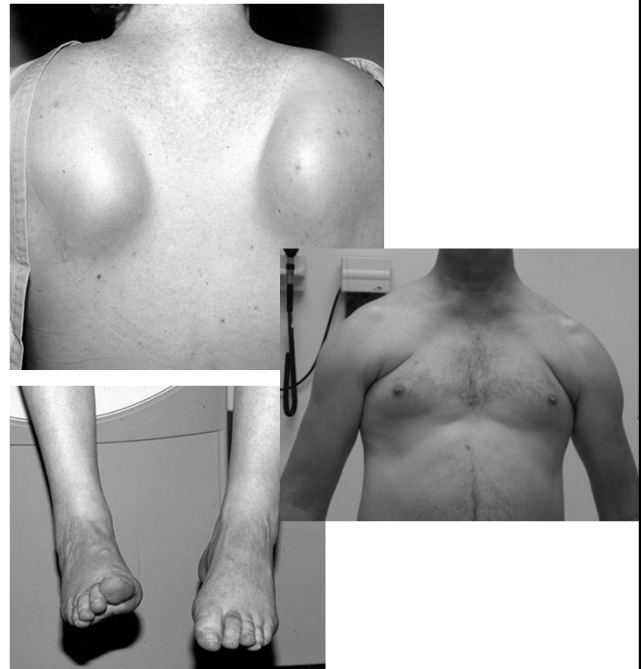
[https://upload.wikimedia.org/wikipedia/commons/9/95/Myotonic\\_dystrophy\\_patient.JPG](https://upload.wikimedia.org/wikipedia/commons/9/95/Myotonic_dystrophy_patient.JPG). No changes made.

## Myotonic Dystrophy 1 (DM1)

- Most common adult muscular dystrophy
- AD inheritance
- Single locus in chromosome 19q13.3
- Dystrophia myotonica protein kinase (*DMPK*) gene with 3' untranslated region with increase in trinucleotide CTG repeats
- Can have anticipation with worsening in subsequent generations.
- Multisystem disease:
  - Cardiac conduction defects -> May need to have pacemaker/defibrillator placed
  - Cardiomyopathy
  - Hypersomnia/sleep apnea
  - Cognitive Impairment
  - Gastrointestinal symptoms
  - Metabolic associated fatty liver disease
  - Insulin insensitivity
  - Cataracts

## Vignette

- 32 y/o female
- Facial weakness
- Sleeps with eyes open
- Cannot whistle
- Difficulty raising arm above shoulder
- Shoulder pain
- Scapular winging
- Foot drop left>right
- Pos. FH with similar symptoms in father

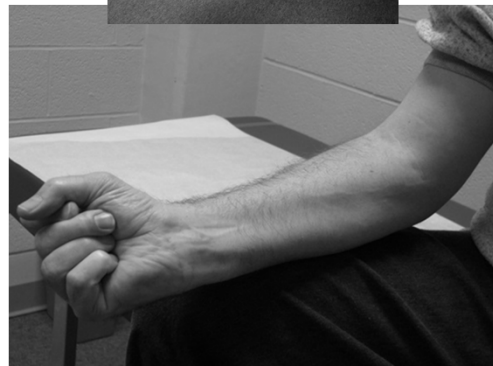
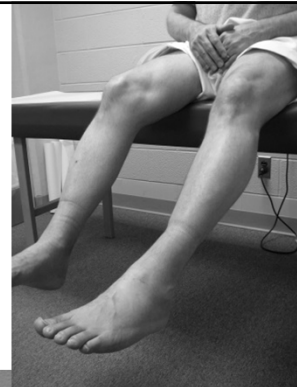
## Fasciocalpulothumeral Dystrophy (FSHD)

- Autosomal dominant linked to 4q35
  - Deletion of 3.3 kb repeated sequence (D4Z4) allowing DUX4 expression
  - Symptoms begin < age 20 in ~ 80%
  - *Typically* begins in face; subtle or absent~4%
  - Shoulder weakness, pain presenting c/o in 80%
  - ~20% asymptomatic at dx
  - 15% will require use of wheel chair
- Mimics**
- LGMD (Calpain)
  - Acid maltase/Pompe deficiency
  - Myofibrillar myopathy
  - Scapuloperoneal dystrophy

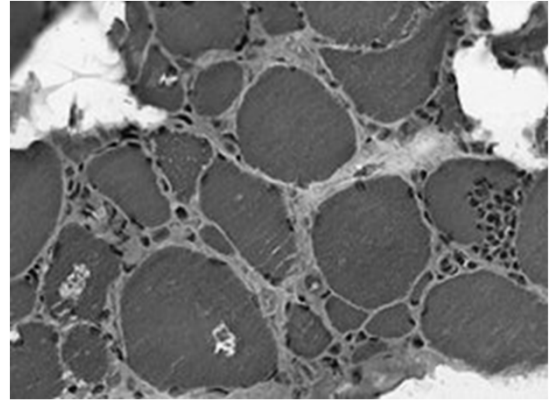
## Vignette

- 52 year old male
- 3 years history of grip weakness and walking difficulty
- Recently trouble swallowing
- Examination
  - Asymmetric wrist and finger flexor weakness
  - Bilateral quad (knee extensor) weakness
  - Facial weakness - mild

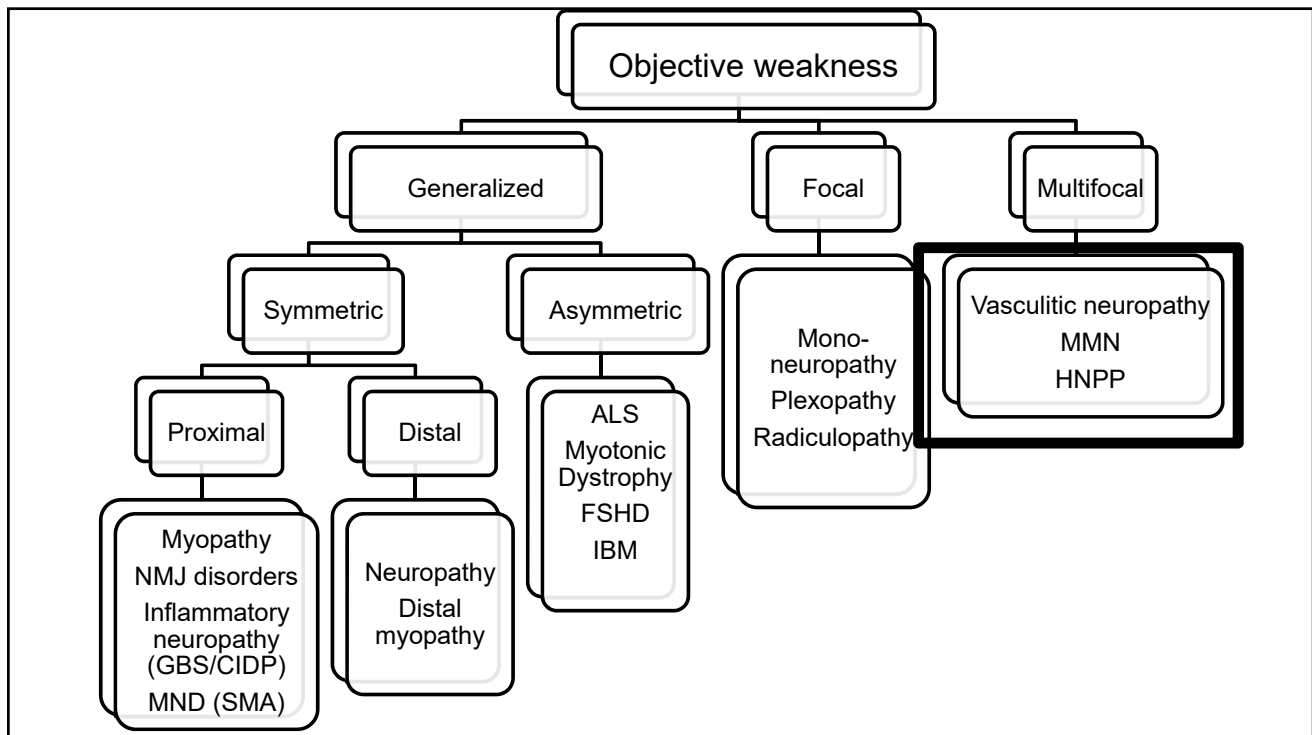


## Sporadic Inclusion Body Myositis (sIBM)

- Commonest IIM after age 50
- More common in men
- Onset: Months-Years
- Dysphagia ~30-60%
- CK: Mild to moderate
- Muscle biopsy is helpful in diagnosis
  - Endomysial inflammatory infiltrate
  - Rimmed vacuoles
  - Protein accumulation or 15- to 18-nm filaments
  - Upregulation of MHC class I
- Not responsive to immunosuppressive Rx

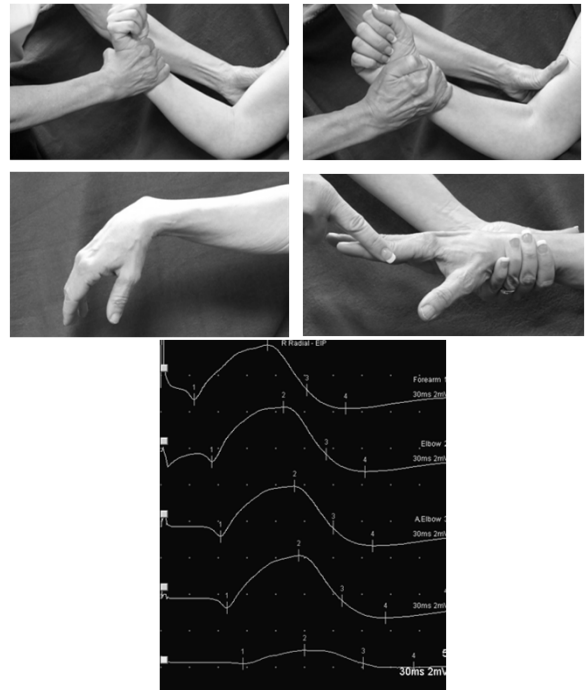


[https://commons.wikimedia.org/wiki/File:IBM\\_rimmed\\_vacuoles\\_HE\\_x200.jpg](https://commons.wikimedia.org/wiki/File:IBM_rimmed_vacuoles_HE_x200.jpg)



## Vignette

- 20 year old college student
- One week history of wrist drop
- No sensory symptoms
- No trauma
- Examination
  - Wrist and finger extension weakness
  - Elbow flexion weakness
  - No sensory deficit



- Hereditary neuropathy with liability to pressure palsies (HNPP)
  - Autosomal dominant
  - PMP22 gene deletion
    - Same gene that causes Charcot Marie Tooth Disease 1A
  - Recurrent and multiple focal neuropathies
    - Trivial compression
  - Commonly involved nerves
    - Peroneal; radial; ulnar; median
- Treatment:
  - Conservative and usually symptoms improve over time
  - Goal is to prevent compressive lesions.

## References

- Hehir MK 2nd, Li Y. Diagnosis and Management of Myasthenia Gravis. *Continuum (Minneap Minn)*. 2022 Dec 1;28(6):1615-1642. doi: 10.1212/CON.0000000000001161. PMID: 36537972.
- Amato A., Russel JA. *Neuromuscular Disorders*, Second Edition. McGraw- Hill Education. 2016.
- Russell JA. General Approach to Peripheral Nerve Disorders. *Continuum (Minneap Minn)*. 2017 Oct;23(5, Peripheral Nerve and Motor Neuron Disorders):1241-1262. doi: 10.1212/CON.0000000000000519. PMID: 28968360.
- Klein, C. J. (2020). Charcot-Marie-Tooth Disease and Other Hereditary Neuropathies. *Continuum (Minneap Minn)*, 26(5), 1224-1256.
- Van den Bergh PYK, van Doorn PA, Hadden RDM, et al. European Academy of Neurology/Peripheral Nerve Society guideline on diagnosis and treatment of chronic inflammatory demyelinating polyradiculoneuropathy: Report of a joint Task Force—Second revision. *Eur J Neurol*. 2021; 3556–3583.

Images (also sited in line):

- [https://commons.wikimedia.org/wiki/File:IBM\\_rimmed\\_vacuoles\\_HE\\_x200.jpg](https://commons.wikimedia.org/wiki/File:IBM_rimmed_vacuoles_HE_x200.jpg). (no changes made)
- [https://upload.wikimedia.org/wikipedia/commons/8/83/FSHD\\_Muscle\\_MRI\\_T1\\_and\\_T2.png](https://upload.wikimedia.org/wikipedia/commons/8/83/FSHD_Muscle_MRI_T1_and_T2.png) (no changes made)
- [https://commons.wikimedia.org/wiki/File:Neuromuscular\\_junction.svg](https://commons.wikimedia.org/wiki/File:Neuromuscular_junction.svg)
- Posey & Spiller, public domain, authors are both more than 70 years death.
- [https://commons.wikimedia.org/wiki/File:ALS\\_clinical\\_picture.png](https://commons.wikimedia.org/wiki/File:ALS_clinical_picture.png). No changes made.
- [https://upload.wikimedia.org/wikipedia/commons/9/95/Myotonic\\_dystrophy\\_patient.JPG](https://upload.wikimedia.org/wikipedia/commons/9/95/Myotonic_dystrophy_patient.JPG). No changes made.